

EXPERIMENTS ON ARTIFICIAL CRYPTORCHIDISM AND LIGATURE OF THE VAS DEFERENS IN MAMMALS

By J. T. CUNNINGHAM, M.A.

(From the Physiological Department, London Hospital Medical College.)

(Received 30th October 1926.)

(With Two Text-figures.)

It has long been known that as a rule the abdominal or undescended testis in man and other Mammals is sterile, and that normal and complete spermatogenesis does not occur in it. Dr F. A. E. Crew⁽²⁾ suggested in 1922 that the cause of this infertility was the higher temperature of the abdominal cavity compared with that of the scrotal cavity. Mr Carl R. Moore⁽⁵⁾ 1922) of the Hull Zoological Laboratories, University of Chicago, made the same suggestion in the same year and has since published evidence in support of it (Moore, C. R.⁽⁶⁾ 1924). He has shown that experimental cryptorchidism produces a condition of the testis essentially similar to natural cryptorchidism. The testis may be made to remain in the body cavity in Rodents, which have a wide and open inguinal canal, by separating the testis from the scrotal wall, pushing it into the abdomen, and closing the inguinal canal with a purse-string suture; by fastening the caput epididymis to the abdominal wall with a suture; or by everting the scrotal sac into the abdomen and securing its walls to the body-wall. In the adult guinea-pig 7 days' retention was sufficient to produce degeneration of the various cells in the different stages of spermatogenesis.

According to Martin, as quoted by Starling⁽⁴⁾, the temperature of the rabbit is $38^{\circ}\cdot7$ C. when the external temperature is 20° C. I have made the following observations, which are open to the criticism that the effect of chloroform and other anaesthetics may prevent the normal regulation of body-temperature, but in taking observations immediately after death from chloroform I have not found great departures from the normal, because there has not been time for any serious loss of heat.

(i) The abdominal temperature of an adult male rabbit (killed by chloroform) was determined by inserting the bulb of a thermometer among the intestines at the posterior end of the abdomen; the scrotal temperature was determined by passing the bulb of the thermometer into the scrotal cavity.

Abdominal temperature	100°·2 F. (37°·9 C.)
Scrotal	„ 96°·2 F. (35°·6 C.)
Room	„ 60°·0 F. (15°·6 C.)

(ii) Observations after death on an adult white rat killed by chloroform gave the following results:

Abdominal temperature		85°·1 F. (29°·5 C.)
Scrotal	„	78°·8 F. (26°·0 C.)
Room	„	60°·0 F. (16°·0 C.)

It is well known that the temperature of the human body can be obtained with close approximation by running the urine over the bulb of a thermometer. I used this method and took the temperature of the human scrotum by wrapping the bulb in a fold of the skin. The results were as follows:

Urine	98°·2 F. (36°·7 C.)
Scrotum	86°·0 F. (30°·0 C.)
Room	57°·2 F. (14°·0 C.)

Moore states ⁽⁶⁾, p. 312 that at a room temperature of 30°·0 C. the difference between the scrotal and abdominal temperatures was often not more than 1°·5 to 2°·0 C., but in one case at room temperature of 16°·0 C. the difference was 8°·0 C.

It is surprising that differences of only 1°·5 to 3°·5 in temperature should determine whether normal spermatogenesis takes place or not, but on the other hand we know that in Mammals, and particularly in man, normal health and even life is limited to a very narrow range of body temperature.

EXPERIMENT ON ARTIFICIAL CRYPTORCHIDISM.

The experiment was performed on February 20th, 1925, on an adult rabbit as follows. The hair was removed from the scrotum with scissors and an ordinary razor before anaesthetising the animal. The skin and muscular wall of the right scrotal sac having been cut through longitudinally, the cauda epididymis was separated from the posterior end of the scrotum, to which it is only slightly connected by fibrous tissue, and then the testis with the epididymis and vas deferens was pushed through the inguinal canal into the abdomen. The inguinal canal was then closed at its anterior end by ligature and the scrotal incision by a suture.

On March 12th, 3 weeks after the operation, the rabbit was killed and the two testes taken out and placed in Bouin's mixture with chromic acid crystals. The testis placed in the abdomen was less than half as large as that which was left in the scrotum. The actual weights were:

Normal, scrotal testis, 4·5 gm.

Abdominal testis, 2·05 gm.

The operated testis lay between the intestines and the wall of the abdomen at the side of the bladder. It had not apparently shifted from the position in which it was placed by the operation.

Sections stained in various ways showed a very marked contrast in microscopic structure between the two testes. Those from the organ left untouched in the scrotum showed the normal structure and normal stages of spermatogenesis in the seminal tubules. The chromosomes in the rabbit's testis are rather thick, numerous,

and crowded, so that it requires careful scrutiny to detect stages of mitosis, but they were distinctly identified in the layer of spermatogonia, and in many of the tubules there were abundant spermatids and spermatozoa. The tubules were touching each other at their most convex parts and the interstitial tissue was therefore scanty.

In sections of the organ placed in the abdomen the tubules are quite abnormal and show no spermatogenesis (Fig. 1). The central part of the cavity of the tubule does not appear empty, but is almost filled with a non-nucleated substance showing indistinct lines radiating towards the centre. Near the wall of the tubule are small scattered nuclei with no cell-outlines; these are the degenerated spermatogonia.

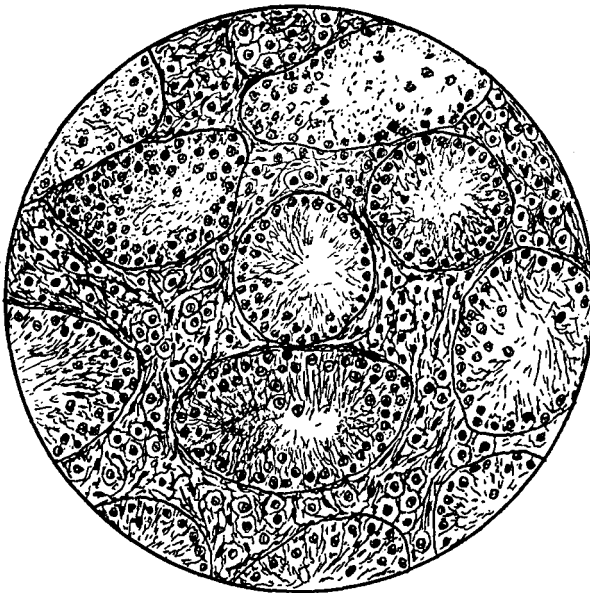


Fig. 1. Section of Testis of Rabbit after artificial retention in the abdomen for 3 weeks. Seminal tubules degenerate, no spermatogenesis. Obj. $\frac{1}{8}$ Watson, Oc. 3 Zeiss.

The external surfaces of the walls of the tubules do not come into contact and the relative amount of interstitial tissue is greater than in the other testis. Whether the amount of intertubular tissue is increased absolutely as well as relatively to the tubules is not certain. Biologists are divided in opinion on the matter and I have not yet tried to decide the question.

Experiments on Ligature of the Vas deferens.

Bouin and Ancel (11) 1903) stated that after ligature of the vas deferens the seminal tubules slowly degenerate and finally disappear while the interstitial tissue persists and manifests the usual cytological evidence of its activity. These authors admitted that many previous investigators had made the same experiment without finding

any degeneration of seminal tubules as a result, but they considered that this was because their predecessors did not wait long enough after the operation. The experiments of Bouin and Ancel were made on guinea-pigs and the post-operative period mentioned by them as sufficient is 102 days or a little over 14 weeks.

Mr Carl Moore and the investigators associated with him have made numerous experiments on rabbits and guinea-pigs, and found that ligature of the vas deferens, provided that the operated testis remains in the scrotum in its normal relations, shows no evidence of degeneration of the seminal tubules nor any injurious effect on spermatogenesis even after a period of 6 months or more than 180 days. They conclude that the discrepancy between the results of different experimenters is due to confusion between the effects of ligature and of abnormal position of the testes, which may be, and probably often has been, caused by the operation. In other words the American investigators believe that the degeneration due to displacement of the testis into the inguinal canal or into the abdominal cavity has been erroneously attributed to ligature of the vas deferens. The experiments which I have made up to the present time entirely confirm the results and conclusions in this respect of Mr Carl Moore and his colleagues.

(i) My first experiment of this kind was made on an adult rabbit which was found before the operation to have its left hind leg completely paralysed, apparently from a former fracture or injury long healed. As there were no signs of pain and the animal was otherwise healthy there seemed no reason for not using it for the experiment. The vas deferens on the left side was ligatured in the abdomen in two places and cut between them. On November 23rd, 3 weeks after the operation, the animal was killed with chloroform. Both testes were found lying in the abdominal entrances of the inguinal canals and the scrotal sacs contracted; usually after death from chloroform the testes are descended and the scrota relaxed. On microscopic examination both testes were found to be completely sterile, the seminal tubules degenerate and without trace of spermatogenesis. This may have been due to old age, or to general conditions of health associated with the old injury to the hind leg. It may have been directly due to the position in which the testes were found. In any case, since the organs were degenerate on both sides, the condition was not due to the operation, which was unilateral.

(ii) A second experiment was performed on January 29th, 1926, also on an adult rabbit. The vas deferens of the left side was ligatured in the abdomen and cut at a point further from the testis. The animal was killed on March 15th, 6 weeks and 3 days after the operation. Both testes after death were found normally descended into the scrotal sacs, and the walls of the sacs perfectly free, without adhesions on the operated side. The occluded vas deferens and cauda epididymis on the operated side were much distended with semen: the testis with epididymis on this side weighed 5.35 gm., on the other side 4.55 gm. Thus, as a result of ligature of the vas deferens, the testis and epididymis together weighed 0.8 gm. more than those left in normal condition, whereas after artificial cryptorchidism the organs of the operated side weighed much less than those of the other.

On microscopic examination of prepared sections the operated testis showed

normal spermatogenesis with no sign of degeneration in the seminal tubules (Fig. 2). The condition of the unoperated testis was in all respects similar. Thus the only effect of ligature was the accumulation in the epididymis of the secretion which was unable to escape.

(iii) A third experiment on an adult male rabbit was performed on February 15th, 1926. An incision was made in the abdominal wall in line with the inguinal canal on the left side. The vas deferens was cut in two places and the piece between the ligatures cut out. The animal was killed on March 20th, 6 weeks and 1 day after the operation. Living and moving spermatozoa were taken from both operated and unoperated sides. As in the previous experiment the cauda epididymis and vas deferens were distended with semen on the operated side. Microscopically the results were in all respects the same as in the preceding experiment. The structure was normal and the seminal tubules showed normal spermatogenesis.

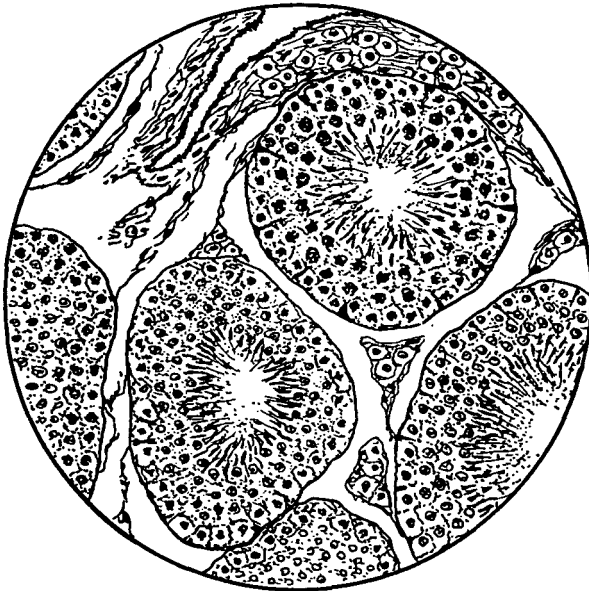


Fig. 2. Section of Testis of Rabbit, Exp. ii, 6 weeks and 3 days after ligature of the vas deferens. Normal spermatogenesis. Obj. $\frac{1}{4}$ Watson, Oc. 3 Zeiss.

DISCUSSION.

It may be suggested that in these experiments on ligature of the vas deferens the interval of time between the operation of ligature and the death of the animal was not long enough to allow the effects of ligature to develop. It is therefore important to notice that the interval in Exps. ii and iii (6 weeks) was twice as long as that which was sufficient to produce complete degeneration of the seminal tubules in the result of artificial cryptorchidism. The interval in my experiments was less than that stated to be necessary by Bouin and Ancel, but on the other hand Steinach records distinct signs of rejuvenation 18 days after ligature of the vasa

deferentia in rats and this rejuvenation he attributes to increase of interstitial-tissue associated with degeneration of the contents of the seminal tubules.

My experiments are chiefly important as a confirmation of the results obtained by the American investigators. Among the conclusions which depend on this type of experimental investigation, the most important are (1) the evolutionary explanation of the descent of the testes and of the origin of the scrotal sacs, and (2) the possibility of rejuvenation of the organism by operative treatment of the testes. It is the first of these questions with which I am here chiefly concerned. In my book *Hormones and Heredity* (1921) and elsewhere I have maintained that the existence of the scrotum and the descent of the testes constitute a character in Mammals which has no utility and therefore is not in accordance with the theory of natural selection. Mr Carl Moore considers that his results disprove my contention, because they show in his opinion that it is the function of the scrotum to keep the gonads at the lower temperature which is necessary for spermatogenesis, and that therefore if the scrotum had not been evolved the Mammalia would have become extinct. In my opinion this is a logical fallacy. We may be certain that in the ancestors of the Mammals the testes were abdominal as in existing Reptiles and Birds. They were certainly functional then and would have remained functional if the change of position which now occurs in development had never been evolved. In fact, they are abdominal in position and yet exhibit normal spermatogenesis in many existing Mammals such as Monotremes, Whales, Seals, Elephants, and Sloths. In Birds the testes are abdominal and function at a temperature considerably higher than that of the abdomen of Mammals. The more correct interpretation of the facts appears to be that the descent of the testes and the consequent formation of a scrotum were due to causes quite unconnected with the function of the testes. The evidence of palaeontology and comparative anatomy indicates that Birds and Mammals were independently evolved from ancient Reptiles, which were of course cold-blooded. Thus in Birds the testes have become adapted to function at a high abdominal temperature (104° in the common fowl) while in Mammals the organs, having become adapted to function at a lower temperature in the scrotum, are now incapable of functioning at the higher temperature of the abdominal cavity.

Steinach (8) 1912) stated that the method of ligaturing the vas deferens in order to exclude the possible hormonal action of the seminal cells was not to be trusted. He had found that even when blood-vessels and nerves were included in the ligature spermatogonia might persist, and in some cases even months after simple ligature regeneration of seminal tubules might occur. He therefore adopted the method of autotransplantation of testes into the young castrated animal to exclude the seminal part of the organ and leave only the intertubular part.

Eight years later (9) 1920) Steinach expresses conclusions which are the opposite of these. In his paper on the production of artificial rejuvenation first in senile rats and afterwards in men, he states that increased growth of the incretory tissue of the testes (that is, of the intertubular tissue which is supposed to be the p which produces an internal secretion) can be caused by ligature of the vas deferens as well as by other methods. But in carrying out the operation in such a small

animal as the rat it was difficult to avoid injury to the blood-vessels running along the vas deferens and therefore he preferred to ligature between the testis and caput epididymis, where in the opinion of Mr Carl Moore there are more important blood-vessels, namely the spermatic artery and vein and their branches, which it is difficult, if not impossible, to avoid.

However, in spite of this, in his first series of experiments on senile rats Steinach adopted the method of ligature of the vas deferens in two places and cutting between them. For example, the vas deferens was ligatured on both sides of a rat, 23 months old, which showed such senile symptoms as deficiency of strength, appetite and courage, and also an absence of sexual vigour. Eighteen days after the operation, the animal showed an improved appetite and increased growth of hair.

From 21 days after the operation, the animal showed the sexual activity and vigour of a young male and this continued for 6 months. It died 8 months and 20 days after the operation.

In the human cases recorded in the paper cited it is to be noted that the operation was only carried out where serious disease of the reproductive organs, such as testicular abscess or hydrocoel, already existed. Thus the marked improvement in health and vigour which is described as the rejuvenation resulting from the increased secretory activity of the interstitial cells caused by ligature of the vas deferens or of the epididymis, might be due to the cure of the disease by the operative treatment which was carried out at the time of the ligature, and which was quite independent of the latter.

In any case it cannot be considered as proved that ligature of the vas deferens produces rejuvenation by causing hypertrophy of the interstitial tissue, because the evidence that ligature causes such hypertrophy is contradicted by the results mentioned in this and other papers. If degeneration of the seminal tubules leads to or is accompanied by increase of the interstitial cells and if this increase causes rejuvenation, then rejuvenation should be produced in Rodents by artificial cryptorchidism. This operation cannot be carried out in man because in this case the inguinal canal is closed.

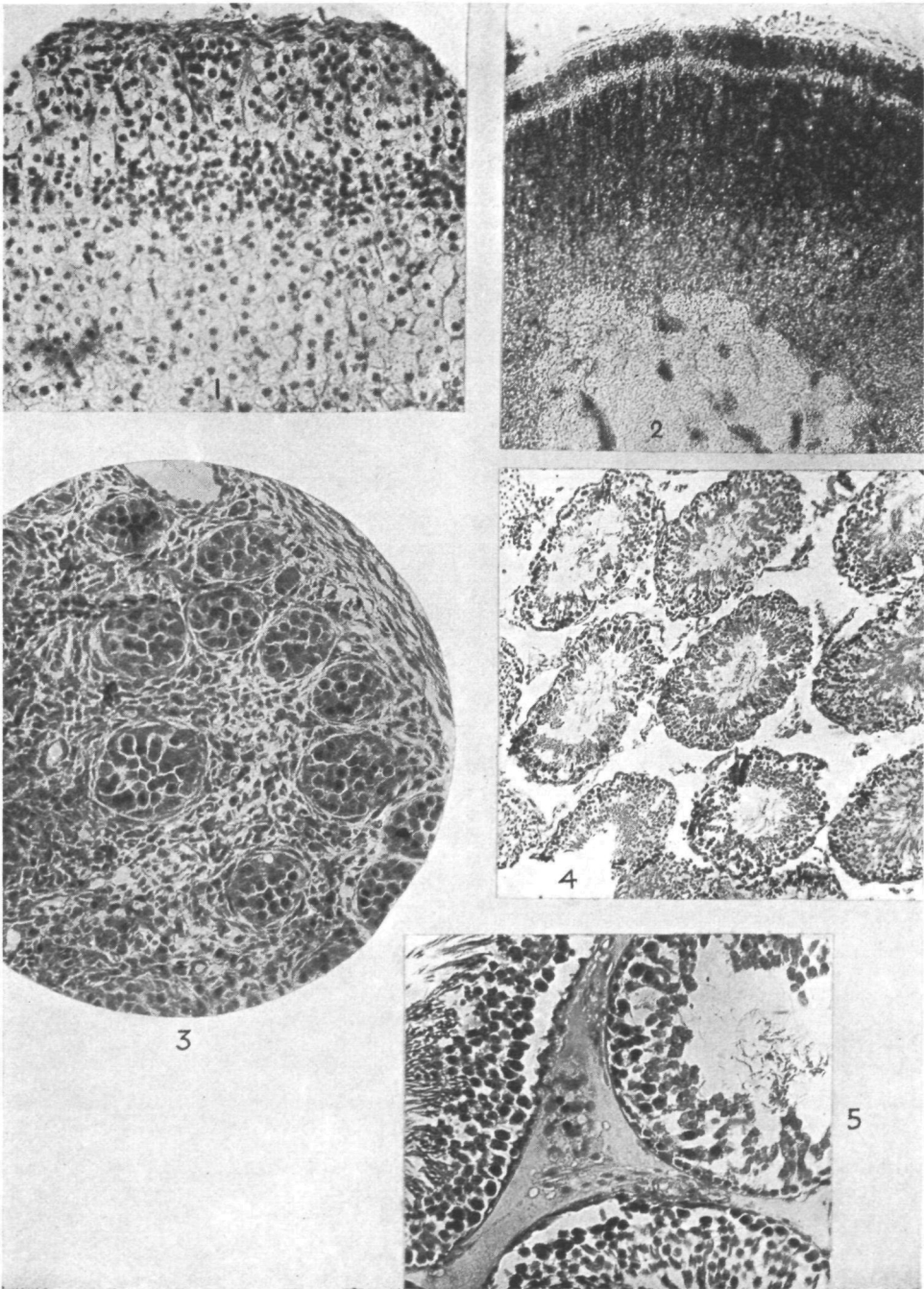
There is, however, evidence that in cases of partially descended testes in the human subject replacement of the organs into the abdomen results in sterility. I have received particulars of one such case in his own practice from Mr Frank Kidd, who has a great reputation as a specialist in the surgery of the urino-genital organs. He was consulted by a young man in whom the testis on each side was incompletely descended, and associated with congenital inguinal hernia. The testes were found to be producing normal, active spermatozoa. A double operation was carried out, the testes replaced in the abdomen, and the herniae stitched up. I infer that in this case the testes and parts of the intestine were before the operation contained in imperfect scrotal sacs communicating with the abdominal cavity. It was not known at that time that normally functioning testes would be rendered sterile by simple placement in the abdomen, but that is what happened in this case. The patient made a good recovery from the operation, but it was subsequently found that the testes had ceased to produce spermatozoa. Mr Kidd also informed me of instances

of corresponding change in the opposite direction. He examined the subsequent results in 17 cases of operation on undescended testes, in which the organs had been drawn down into the scrotum, and in every case in which they had remained in their new position the testes were found to have become normally functional and fertile.

In rats and other Rodents the inguinal canal is widely open and the testes can be, and often are, withdrawn into the abdominal cavity. The posterior end of the testis, or rather of the cauda epididymis, is attached to the posterior end of the wall of the scrotum. This part of the muscular wall of the pouch is usually found more or less inverted and the inverted part forms the so-called gubernaculum. Withdrawal of the testis is produced by contraction of the transverse fibres of the muscular wall of the scrotum which presses the testis into the abdomen, and this involves the complete inversion of the wall.

Steinach's description of his technique (1920) suggests that the testes may have remained in the body cavity after operation and that this retention was the cause of the degeneration of seminal tubules and increase of interstitial tissue to which he attributes the rejuvenation. This suggestion, however, is contradicted by his descriptions of the condition of some of his rats before and after ligature of the vasa deferentia. He states that before operation the scrota were empty, the testes in the body cavity, while three or four weeks after operation the scrota were full and the testes descended. He also states that at the time of operation the testes were seen to be atrophied and small, in one case scarcely half as large as in the normal adult. It may be suggested that the first result of ligature in Steinach's experiments, as in mine, was enlargement of the epididymis in consequence of retention of semen. On the other hand, Steinach figures a section of the testis of a rat 5 weeks after ligature between testis and epididymis, and this shows the same degenerate characters as those seen in my second experiment. Another figure (9), Taf. XXIX, Fig. 1) shows the same condition $2\frac{1}{2}$ months after unilateral operation of the same kind. Two other figures show the condition of one testis 4 weeks after operation and the other 9 months after from the same animal. The first shows the characteristic degenerate condition, the other shows the greater number of the seminal tubules fully regenerated and in a state of active spermatogenesis. In the paper referred to Steinach gives no figures or description of degeneration in the testis after ligature of the vas deferens, although he describes the symptoms of rejuvenation following the operation.

The experiments described in this paper were carried out in the Physiological Department of the London Hospital Medical College, and I have much pleasure in here expressing my thanks to the authorities of the College for permission to work there and especially to Prof. Roaf for placing the facilities of his Laboratories at my disposal.



WATSON—THE RELATIONSHIP OF THE CORTEX SUPRARENALIS AND TESTES THROUGHOUT LIFE IN THE RAT (pp. 342-348).

SUMMARY.

Observations are recorded showing that the temperature of the scrotal cavity is lower than that within the abdomen.

An experiment is described in which the testis was displaced from the scrotal cavity to the abdominal cavity, and after 3 weeks the seminal tubules were found to be reduced in size and their contents degenerate with no spermatogenesis, while the interstitial tissue was relatively increased.

Experiments are recorded in which ligature of the vas deferens was carried out and after 6 weeks the contents of the seminal tubules showed the stages of normal spermatogenesis.

These and similar results obtained by Moore and others are interpreted as showing that although a lower temperature is essential for spermatogenesis in Mammals, it is not correct to state that the maintenance of this lower temperature is the function of the scrotum and that this was essential for the evolution of Mammals. The adaptation of spermatogenesis to temperature is the consequence of the evolution of the scrotum, which was due to causes independent of the function of the testes.

My results do not support Steinach's theory that rejuvenation depends on increase of the interstitial cells of the testis, and that this increase can be produced by ligature of the vas deferens.

REFERENCES.

- (1) BOUIN and ANCEL (1903). "Recherches sur les cellules interstitielles du testicule des mammifères." *Arch. de zool. expér. et gén.* 4, 1.
- (2) CREW, F. A. E. (1922). "A Suggestion as to the Cause of the aspermatic Condition of the imperfectly descended Testis." *Journ. of Anatomy*, 56.
- (3) CUNNINGHAM, J. T. (1921). *Hormones and Heredity*. London, Constable and Co.
- (4) MARTIN C. J. (1903). "Effect of external Temperature on Body-Temperature, etc." *Phil. Trans. Roy. Soc.* 195 B. See also Starling, *Principles of Human Phys.* 4th edit. p. 992.
- (5) MOORE, C. R. (1922). "Cryptorchidism experimentally produced." *Anat. Record*, 24, 383.
- (6) — (1924). "Properties of the Gonads, etc. VI. Testicular Reactions in experimental Cryptorchidism." *Am. Journ. Anat.* 34.
- (7) — (1924). "Properties of the Gonads, etc. VIII. Heat application and testicular Degeneration." *Amer. Journ. Anat.* 34.
- (8) STEINACH, E. (1912). "Willkürliche Umwandlung von Säugethiermännchen, in Thiere mit weiblichen Geschlechtscharakteren." *Pflüger's Archiv*, 144.
- (9) — (1920). "Verjüngung durch experimentelle Neubildung der alternenden Pubertätsdrüse." *Arch. f. Entwicklungsmechanik*, 46.